

Opportunities of modern cone-beam CT scanners in assessment of changes of distal extremities

Authors: A. Vasiliev, N. Blinov, E. Egorova, D. V. Makarova, E. G. Gorlycheva; Moscow/RU

Aims and objectives

Injuries and diseases of musculoskeletal system occupy the 4th place in the overall structure of morbidity in the world and are located on the 2nd place among the causes of temporary disability [2, 4, 6]. Incident rate among the adult population in Russian Federation reaches 94,4 cases per 1000. Among all the fractures 86,6 % are localized on extremities [1]. The primary study of changes and characteristics of bone structure in cases of injuries and diseases of musculoskeletal system is limited mostly by a standard radiography. But it is worth noting that traditional x-ray examination can provide not all the information about topography of such complex anatomical segments by its compound, as wrist, foot, ankle and hand [6, 7, 9 – 11].

Despite the obvious advantages, cone-beam computed tomography (CBCT) still does not have a wide application in everyday clinical practice for distal extremity's researches [3, 5, 8, 11, 12]. In the framework of our research CBCT capabilities in assessment of changes of distal extremities have been analyzed. For this purpose: the cone-beam-semiology of bone structure changes has been précised; an assessment of efficiency (specificity (Sp), accuracy (Ac), sensitivity (Se)) of CBCT in characteristic of the bone structure was carried out; recommendations on application of CBCT in the diagnostic algorithm in the study of distal segments of the upper and lower extremities were worked out.

Methods and materials

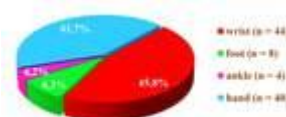


Fig. 1: CBCT-examinations of wrists have been conducted to 44 (45,8 %) patients, of...

In total, 96 patients at the age from 24 to 65 years with posttraumatic changes and diseases of distal segments of upper and lower extremities were examined on modern CBCT-scanner – NewTom 5G (QR S.r.l., Italy) (Fig. 1). Among all the examined patients 42,7 % (n = 41) of them were with posttraumatic changes, 57,3 % (n = 55) – with diseases of distal extremities.

To assess diagnostic efficiency of CBCT, its results were compared with the data of multislice computed tomography (MSCT) of patients with a similar pathology, which was conducted on Brilliance 64 (Philips, Netherlands) in 100,0 % (n = 96) cases. In 33,3 % (n = 32) cases magnetic resonance tomography (MRI) of distal extremities was carried out on Centauri MPF 3000 (XinAO MDT, China), ultrasound examination (US) – on iU-22 (Philips, Holland) in 15,6 % (n = 15) cases, digital microfocus radiography (DMFR) was carried out on X-ray unit Pardus (Russia) and standard radiography (SR) of wrists, hands, feet and ankles to 46,9 % (n = 45) patients (Fig. 2).

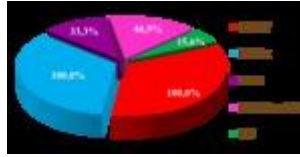


Fig. 2: CBCT-images have been compared with the data of MSCT, MRI, US, DMFR and SR of...

Results

Received CBCT-images of distal segments of upper and lower extremities were distinguished by high-resolution with a detailed mapping of bone structure: accurate differentiation and direction of bone trabeculae. It became possible to measure a thickness of cortical bone, even if it was less than 1 mm. During the comparative analysis it was found that visualization of bone structure on CBCT-images was comparable or even exceeded MSCT and digital microfocus X-ray images, but it was not defined reliable on standard X-ray images. In addition, small bone fragments and areas of pathological alteration of bone tissue (even under 1 – 2 mm) were observed reliably on CBCT-images. It became possible to specify its localization and spatial location (Fig. 3, 4).

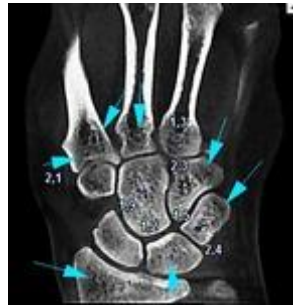

Fig. 3: CBCT-image of the left wrist with the detailed mapping of the bone structure...

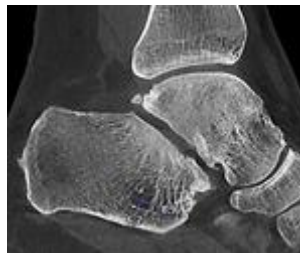


Fig. 4: CBCT-image of the right ankle with the detailed mapping of the bone structure

The signs of different kinds of fractures in 42,7 % (n = 41) cases were visualized reliably on CBCT with subsequent building of multiplanar and 3D-reconstructions. Osteoreparation abnormality process (false joints, neoarthrosis, avascular necrosis) was detected in 18,8 % (n = 18) cases. The absence of the callus, smoothing and curving of bone fragments and detection of closing plates at the level of the edges of fragments in the presence of false joints and signs of avascular necrosis as areas of osteosclerotic changes with a loss of trabecular structure, surrounded by a rim of sclerosis, were revealed convincing on MSCT and CBCT. It was not always possible to establish the presence of the closing plates at the level of the edges of fragments or the signs of avascular necrosis by SR (Fig. 5–8).

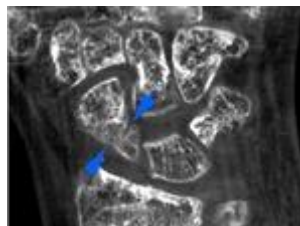


Fig. 5: The signs of formation of the false joint of the scaphoid of the left wrist are...

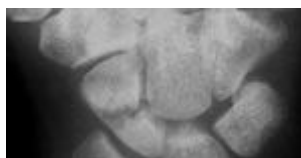

Fig. 6: The convincing data of the closing plate is not received on the SR

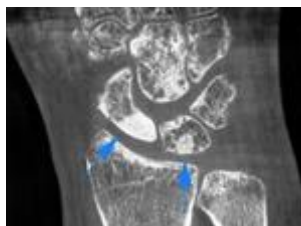

Fig. 7: The signs of avascular necrosis of the proximal fragment of the scaphoid and...

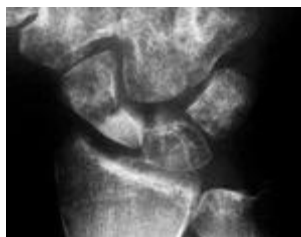

Fig. 8: The convincing data of avascular necrosis of the lunate bone is not received on...

Our attention was attracted by the lack of significant artifacts from different kinds of massive metal constructions, foreign bodies with metal density and cell employ bandages on CBCT-images as distinct from MSCT (Fig. 9, A–E).

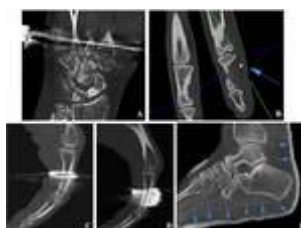


Fig. 9: There is no significant artifacts from the reduction apparatus (A), the foreign...

CBCT-images of distal extremities were characterized by high spatial resolution, optimal signal-to-noise ratio, uniform accuracy and dynamic range grayscale, which allowed estimating not only of bone structure, but dense soft tissue formations as well: capsule-ligamentous apparatus, tendons, palmar and plantar aponeurosis, clusters of excess fluid accumulation in sinovitis and tendovaginitis (Fig. 10, A, B). These CBCT-findings were comparable with MSCT, but were not always convincing by SR and DMFR.

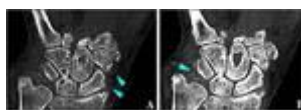


Fig. 10: CBCT-images with the presence of the tightened collateral ligaments of the...

We also managed to determine reliably the presence of the tofuses on CBCT-images of patients with podagric arthropathy in 27,1 % (n = 26) cases. It became possible to ascertain its size, localization, spatial location and to assess the relationships with the surrounding tissues (Fig. 11, 12). CBCT-visualization of crystals of uric acid accumulation was comparable with MSCT and DMFR, but was not always convincing by SR.

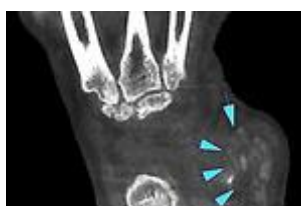

Fig. 11: CBCT-image of the wright wrist with the presence of the podagric tofus (blue...

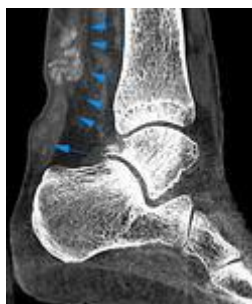

Fig. 12: CBCT-image of the wright ankle with the presence of the podagric tofuses during...

In 22,9 % (n = 22) cases signs of palmar, palmar-finger forms of Dupuytren's contracture and of plantar aponeurosis degeneration were detected. Funnel-shaped retraction of skin on a palm or a foot surface, restriction of extension of one or more fingers on the level of changes, as well, associated with degeneration of one or more beams of aponeurosis defined with external inspection. During comparative analysis of MSCT, MRI, US and CBCT-images we noted the signs of fibrous degeneration of palmar or plantar aponeurosis as a limited retraction of the skin under it. A thickened connective tissue cords have been visualized reliably between skin and aponeurosis, an edge between them differentiated separately not always. A significant thickening of the aponeurosis with a heterogeneous structure and illegible, uneven outline subcutaneously at this level has been determined. A modified aponeurosis was commissured with tendon and skin depending on the stage or form of the contracture in a varying degree. There were initial signs or symptoms of a severe deformity of the tendon on this background. Moreover, all the above-listed studies (MSCT, MRI, US and CBCT) of patients with signs of aponeurosis degeneration revealed the presence of tenosinovitis of flexor fingers and degenerative-dystrophic changes in bones of distal segments of involved extremities (Fig. 13, A–C). An assessment of SR of distal extremities didn't not allowed us to obtain any data about palmar or plantar aponeurosis of such patients.

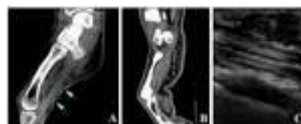


Fig. 13: CBCT (A), MSCT (B) and US (C) images of patients with Dupuytren's contracture

Conclusion

The obtained data of the comparative analysis evidenced a high efficiency of CBCT in diagnostics and dynamic researches of a number of injuries and diseases of upper and lower extremity's distal segments. CBCT showed a high efficiency (Se, Sp, Ac – 100%) at the detection of small areas of pathological remodeling and post-traumatic changes of the bone tissue, which size was less than 1 – 2 mm. Taking into consideration significant advantages of CBCT (high quality of images, low dose, lack of significant artifacts from high density materials and an opportunity to assess a state of dense soft tissue structures and to identify an accumulation of fluid excess in the joints, synovial bursas and tendon sheaths) it is necessary to revise an algorithm of examination of such patients. CBCT can be recommended as a priority method of the first stage for diagnostics and dynamic researches of injuries and diseases for such complex anatomical segments by its compound, as wrist, foot, ankle and hand, where summational effect pronounced mostly on SR.

References

1. Andreeva T. M., Ogryzko E. V., Red'ko I. A. Injuries in Russian Federation at the beginning of new Millennium. // Moscow.: Vestn. travmatol. orthoped. 2007. № 2. P.59–63.
2. Chulovskaya I. G. Complex diagnostics of diseases and injuries of soft tissues of the hand and forearm: thesis for a Doctor's degree. Moscow: Russian national research medical University named after N. I. Pirogov Health Ministry of Russia, 2012. 388 p. (in Russian).

3. De Cock J., Mermuys K., Goubau J., Van Petegem S., Houthoofd B., Casselman JW. Cone-beam computed tomography: a new low dose, high resolution imaging technique of the wrist, presentation of three cases with technique. // *Scelet. Radiol.* 2011. V. 41. P.93–96.
4. Duckworth A. D., Jenkins P. J., Aitken S. A., Clement N. D., Court-Brown C. M., McQueen M. M. Scaphoid Fracture Epidemiology. // *J. Trauma Acute Care Surg.* 2012. V. 72. № 2. P. 41–45.
5. Faccioli N., Foti G., Barillari M., Atzei A., Mucelli R. Finger fractures imaging: accuracy of cone-beam computed tomography and multislice computed tomography. // *Skeletal. Radiol.* 2010. № 39. V 11. P. 1087–1095.
6. Geijer M. Diagnosis of scaphoid fracture: optimal imaging techniques. // *Rep. in Med. Imag.* 2013. V. 6. P. 57–69.
7. Kokkonen H. Development and Evaluation of Delayed CT Arthrography of Cartilage // *Acad. Diss.* 2012. 84 p. (Publications of the University of Eastern Finland Dissertations in Forestry and Natural Sciences No 91).
8. Mattila K., Kankare J. A., Kortensniemi M., Salo J., Lindfors N. C., Mattila J. T., Koshkinen S. K. Cone-beam for extremity imaging. // *ESR-2013. EPOS.* 2013.
Epub.: http://posterng.netkey.at/esr/online_viewing/index.php?module=view_postercoverpage&task=viewcoverpage&pi=106423
9. Nakonechniy D. G. Fractures of hand, arm and forearm bones, and properly fused or slow intergrowing: false joints, deformations, defects of wrist bones (clinical protocol), 2013. Saint-Petersburg: Russian scientific research Institute of traumatology and orthopedics named after R. R. Vreden Health Ministry of Russia.
Epub.: <http://www.cito-priorov.ru/news/cf7419c4-1a4a-47ca-9093-eed011361158.html> (in Russian).
10. Pugacheva E. N. Ultrasound diagnosis of soft tissue formations of the locomotor system: Abstract MD. Saint-Petersburg: Saint-Petersburg medical Academy of postgraduate education of the Federal Agency of healthcare and social development, 2011. 129 p. (in Russian).
11. Tohka S. Extremity imaging with cone beam computed tomography. // *HIRE* 2011. V. 6. 4. P. 39–41.
12. Tuominen E. K. J., Kankare J., Koskinen S. K., Mattila K. T. Weight-Bearing CT maging of the Lower Extremity. // *Am. J. of Roentgen.* 2013. V. 200. № 1. P. 146–148.
13. Watanabe A., Souza F., Vezeridis P.S., Blazar P., Yoshioka H. Ulnar-sided wrist pain. II. Clinical imaging and treatment. // *Skeletal Radiol.* 2010. V. 39. P. 837–857.